EXCELLENCE IN DERMATOLOGY™

zoetis™

CLINICAL KNOWLEDGE INSIGHTS

IMMUNE-MEDIATED DERMATOSES

PEMPHIGUS FOLIACEUS

Clinical Knowledge Insight created by **Andrew Hillier, BVSc, MACVSc, DACVD**

CONTENTS

AT A GLANCE : 15.1
WHAT DOES IT LOOK LIKE? : 15.2
PATHOLOGIC IMAGE LIBRARY : 15.3
WHAT ELSE LOOKS LIKE IT? : 15.4
HOW DO I DIAGNOSE IT? : 15.4
HOW DO I MANAGE IT? : 15.5
COMMENTS : 15.6
REFERENCES : 15.6

AT A GLANCE

- The Pemphigus complex is a group of autoimmune skin diseases
- The most common variant is pemphigus foliaceus (PF)
- Other variants seen in dogs include:
  - → Pemphigus vulgaris (PV)
  - → Pemphigus vegetans (PVeg)
  - → Pemphigus erythematosus (PE)
  - → Paraneoplastic pemphigus (PNP)
- Autoantibodies are directed against protein antigens in desmosomes which are the intercellular connections between skin cells (keratinocytes) (What Does it Look Like, Figure 1).

APQ0413040 © 2013 Zoetis Inc. All rights reserved. May 2013.

- For example, in dogs with PF, the autoantodies are thought to be primarily directed at desmocollin 1, whereas in PV they are directed at desmoglein 3.
- The precise mechanism by which the autoantibodies breakdown the intercellular connections (a process referred to as acantholysis) is still uncertain.
- Uncommonly, drugs may cause PF in either of 2 syndromes:
  - → Drug-induced PF: disease goes into remission with drug withdrawal
  - → Drug-triggered PF: drug initiates disease that persists despite drug withdrawal
- Exposure to sunlight can worsen the lesions of PF
- Breed predilections include Akitas and Chow-chows, although Golden Retrievers, Cocker Spaniels, Dachshunds, Doberman pinschers and English Bulldogs have also been reported to be over-represented.
- The disease typically affects middle age dogs although dogs < 1 year of age have been rarely reported.

WHAT DOES IT LOOK LIKE?

- PF is characteristically a pustular disease *(Pathologic Image Library – Figure 2)*. Pustules are typically large (spanning many hair follicles) but may be smaller (pinpoint) in a minority of cases
- In some patients, papules (precursor of pustules) are more prominent, while in others there is rapid pustule rupture and the predominant lesions are therefore crusts *(Pathologic Image Library – Figure 3)*
- Post-lesional erosions and alopecia may predominate
- The head, face and ear pinnae are most commonly affected initially with bilateral symmetry
- In most dogs, lesions eventually generalize, sometimes rapidly *(Pathologic Image Library – Figure 4)*
- The footpads may have significant involvement with crusts and fissures, leading to lameness in some patients *(Pathologic Image Library – Figure 5)*
- The lesions may wax and wane in severity
- Lesions are rarely pruritic
- A few patients are depressed and may have a fever

APQ0413040 © 2013 Zoetis Inc. All rights reserved. May 2013.

PATHOLOGIC IMAGE LIBRARY : PEMPHIGUS FOLIACEUS

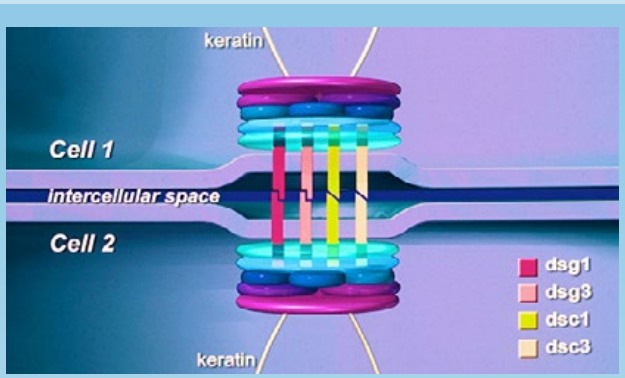

Figure 1. (left) Schematic of a desmosome and some of the protein elements that are targets for autoantibodies in patients with Pemphigus Foliaceus (PF).

Figure 2. (center) 2.5 y.o. Collie - early lesions of PF. Note: generalized erythema & alopecia - bridge of nose; multiple pustules, many spanning several hair follicles.

Figure 3. (right) Chinese Shar Pei with severe alopecia, hyperpigmentation & coalescing crusts on the face, head and pinna. Bilateral symmetry, absence of pustulesdepigmentation and the loss of the typical cobblestone architecture of the nose.

Figure 4. 4 y.o. Scottish deerhound (lateral chest shaved). Erythematous pustules, several > 1 cm spanning multiple hair follicles; right - recently ruptured pustule.

Figure 5. Moderate to severe crusting of all footpads in a dog with PF. Pustules are rarely visible on footpads - lesions may become erosive, and ulcerated

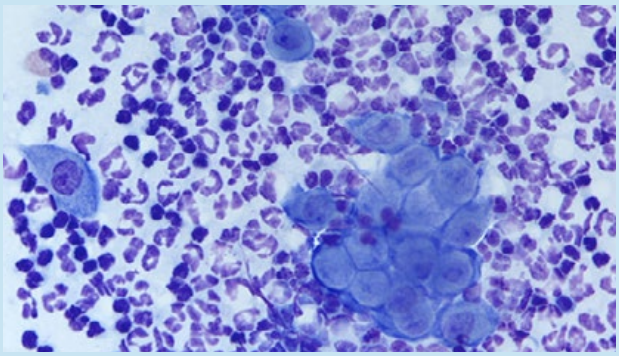

Figure 6. Cytology of purulent contents of lesions. Inflammatory infiltrate predominantly neutrophilic; plentiful acantholytic keratinocytes, large raft of acantholytic cells.

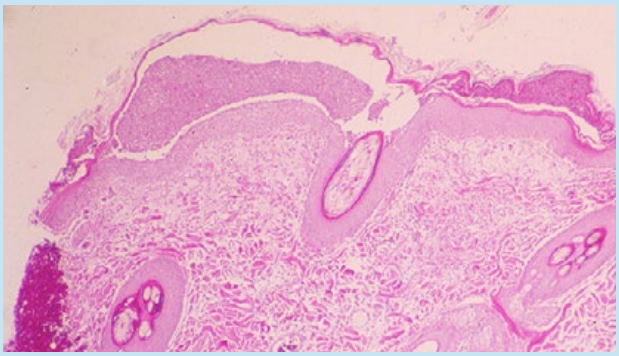

Figure 7. Histopath. of intact pustule. Stratum corneum separated from underlying epidermis by inflammation; spans several follicular units; advances down hair follicle.

All Photos: Case Material from the Dermatology and Otology Service, The Ohio State University

APQ0413040 © 2013 Zoetis Inc. All rights reserved. May 2013.

WHAT ELSE LOOKS LIKE IT?

PUSTULAR CRUSTING DERMATITIS

- Staphylococcal pyoderma
- Demodicosis
- Dermatophytosis (especially Trichophyton infection)
- Subcorneal pustular dermatosis (very rare)
- Eosinophilic pustulosis (very rare)
- PE (if limited to the head)

FOOTPAD CRUSTING AND FISSURES

- Superficial necrolytic dermatitis
- Zinc-responsive dermatosis
- Cutaneous lymphosarcoma
- Canine distemper

HOW DO I DIAGNOSE IT?

RULE OUT DIFFERENTIAL DIAGNOSES

- Superficial pyoderma (negative cytology, negative bacterial culture, lack of response to antibiotic therapy)
- Demodicosis (negative deep skin scraping)
- Dermatophytosis (negative DTM culture)

PUSTULE CYTOLOGY (WHAT DOES IT LOOK LIKE, PATHOLOGIC IMAGE LIBRARY – FIGURE 6)

- Plentiful neutrophils
- Acantholytic cells, especially if present in groups (so called “rafts”)
- Eosinophils may be present or predominate in a few cases
- Absence of coccoid bacteria

BIOPSY

- Sample intact and entire pustules for best results. Fresh crusts may be useful if pustules are not present
- Subcorneal pustules spanning several hair follicles with neutrophils, acantholytic cells and occasionally eosinophils are characteristic *(Pathologic Image Library – Figure 7)*

CBC, BIOCHEMISTRY PROFILE AND UA

- Neutrilia may be present ophbut all other values are typically within normal limits.

APQ0413040 © 2013 Zoetis Inc. All rights reserved. May 2013.

OTHER TESTS (RARELY PERFORMED)

- Direct immunofluorescence (detection of autoantibodies in the skin) may require submission of fresh frozen skin or in Michels medium; some laboratories perform IHC or DIF on formalin-fixed tissues (contact laboratory)
- Indirect immunofluorescence (detection of circulating autoantibodies) is typically insensitive and inconsistent and is not recommended at this time

DIAGNOSTIC TECHNIQUES VIDEOS: ExcellenceInDermatology.com → Education Library → Videos

DIAGNOSTIC TECHNIQUES SECTIONS: ExcellenceInDermatology.com → Diagnostic Techniques

HOW DO I MANAGE IT?

GENERAL POINTS

- Do no harm!
- Keep patient protected from sunlight
- Consider if the disease may be drug-related and withdraw any suspect drugs
- Frequent bathing (shampoo q 2x weekly) to remove crusts

LOCALIZED PF: TOPICAL THERAPY FIRST

- Topical corticosteroids applied q 12 hrs. Start with more potent corticosteroids (e.g. betamethasone or dexamethasone) until remission is achieved, then convert to less potent corticosteroids for long-term control (e.g. hydrocortisone or prednisolone)
- Topical tacrolimus applied q 12 hrs may also be considered

GENERALIZED PF: SYSTEMIC THERAPY NECESSARY

CORTICOSTEROIDS

→ Prednisone or prednisolone 1-3 mg/kg q 12-24 hrs (the author typically starts with 1-2 mg/kg q 12 hrs), Significant improvement is typically seen within 2 weeks, then commence slow taper over 2-3 months aiming for a maintenance dose of prednisone < 1 mg/kg q 48 hrs.

IF POOR RESPONSE TO INITIAL PREDNISONE/PREDNISOLONE CONSIDER:

→ Increase the dose of prednisone/prednisolone if patient is tolerating the drug well

→ Change the corticosteroid (triamcinolone or dexamethasone) – beware of increased risk of gastrointestinal side effects. Dexamethasone and triamcinolone are usually dosed at 1/10th the dose of prednisone

→ Add azathioprine at 2 mg/kg q 24-48 hrs

→ Try the combination of doxycycline (5-10 mg/kg q 12 hrs) and niacinamide (dogs < 10 kg 250 mg q 8 hrs; dogs > 10 kg 500 mg q 8 hrs)

→ Add cyclosporine (5-10 mg/kg q 24 hrs)

APQ0413040 © 2013 Zoetis Inc. All rights reserved. May 2013.

OTHER AGGRESSIVE TREATMENTS INFREQUENTLY USED

→ Human IV immunoglobulin

→ Mycophenolate mofetil (10-20 mg/kg q 12 hours)

→ Cyclophosphamde (2.2 mg/kg q 48 hrs)

→ Chlorambucil (0.1-0.2 mg/kg q 24-48 hrs)

COMMENTS

- PF is the most common autoimmune skin disease of dogs
- Typically middle-aged dogs are affected with Akitas and Chow-chows being particularly predisposed
- PF is a pustular to crusting dermatitis affecting the head and pinnae initially but then generalizes
- Diagnosis is determined by cytology and histopathology
- The prognosis for the disease is good although treatments may have significant side effects and are long term

REFERENCES

- August JR, Chickering WR. Pemphigus foliaceus causing lameness in four dogs. *Compend Contin Educ Pract Vet* 1985; 7: 894-902.
- Gomez SM, Morris DO, Rosenbaum MR, et al. Outcome and complications associated with treatment of pemphigus foliaceus in dogs: 43 cases (1994-2000). *J Am Vet Med Assoc* 2004; 224(8): 1312-1316.
- Gross TL, Ihrke PE, Walder EJ, et al. Pustular diseases of the epidermis. Skin diseases of the dog and cat. 2nd ed. Ames, Iowa: Blackwell, 2005; 3-26.
- Ihrke PJ, Stannard AA, Ardans AA, et al. Pemphigus foliaceus in dogs: a review of 37 cases. *J Am Vet Med Assoc* 1985; 186(1): 59-66.
- Ihrke PJ, Stannard AA, Ardans AA, et al. Pemphigus foliaceus of the footpads in three dogs. *J Am Vet Med Assoc* 1985; 186(1): 67-69.
- Miller WH, Griffin CE, Campbell KL. Autoimmune and immune-mediated dermatoses. Muller and Kirk's Small animal dermatology (7th ed). St. Louis MO.: Elsevier Mosby, 2013; 432-500.
- Mueller RS, Krebs I, Power HT, et al. Pemphigus foliaceus in 91 dogs. *J Am Anim Hosp Assoc* 2006; 42 (3):189-196.
- Olivry T. A review of autoimmune skin diseases in animals: I—superficial pemphigus. *Vet Dermatol* 2006; 17(5):291-305.
- Olivry T, Dunston SM, Walker RH, et al. Investigations on the nature and pathogenicity of circulating antikeratinocyte antibodies in dogs with pemphigus foliaceus. *Vet Dermatol* 2008; 20(1):42-50.

APQ0413040 © 2013 Zoetis Inc. All rights reserved. May 2013.

- Peters J, Scott DW, Erb HN, et al. Comparative analysis of canine dermatophytosis and superficial pemphigus for the prevalence of dermatophytes and acantholytic keratinocytes: a histopathological and clinical retrospective study. *Vet Dermatol* 2007; 18(4):234-240.
- Rosenkrantz WS. Pemphigus: current therapy. *Vet Dermatol* 2004; 15(2):90-98.
- Tater KC, Olivry T. Canine and feline Pemphigus foliaceus: Improving your chances of a successful outcome. *Vet Med* 2010; January: 18-30.
- Yabuzoe A, Shimizu A, Nishifuji K, et al. Canine pemphigus foliaceus antigen is localized within desmosomes of keratinocyte. *Vet Immunol Immunopathol* 2009; 127(1-2):57-64.

APQ0413040 © 2013 Zoetis Inc. All rights reserved. May 2013.